



# Bullet Migration from Fascial Space of Femoral Vein to Common Iliac Vein Bifurcation

Mustafa Talip Şener<sup>1</sup>, Çağrı Kara<sup>1</sup>, İsmail Malkoç<sup>2</sup>, Akın Levent<sup>3</sup>, Ahmet Neziğ Kök<sup>1</sup>

<sup>1</sup>Department of Forensic Medicine, Atatürk University School of Medicine, Erzurum, Turkey

<sup>2</sup>Department of Anatomy, Atatürk University School of Medicine, Erzurum, Turkey

<sup>3</sup>Department of Radiology, Atatürk University School of Medicine, Erzurum, Turkey

**Cite this article as:** Şener MT, Kara Ç, Malkoç İ, Levent A, Kök an. Bullet Migration from Fascial Space of Femoral Vein to Common Iliac Vein Bifurcation. J Emerg Med Case Rep 2017; 8: 73-5.

## ABSTRACT

**Introduction:** Migration of a retained bullet in the body is rare. Some studies have reported regarding embolism induced by intravascular bullet migration. Here we present a case of lead bullet migration through the external surface of the right femoral vein.

**Case Report:** A 31-year-old male was referred to our department for clinical forensic medical evaluation. He was assaulted while working at his office and thus was subsequently taken to the emergency department. Physical examination revealed that the bullet first entered from the left thigh and passed through the medial part of the right thigh with its own kinetic energy, and after 7 h, it passively moved up to the common iliac vein via the femoral space of the right femoral vein.

**Conclusion:** This case report is important as it demonstrated that the lead bullet retained in the body may have passively migrated toward proximal and abdomen via the external surface of the vein between the fascia and intermuscular structures.

**Keywords:** Gunshot wound, bullet migration, interfascial space, femoral vein

**Received:** 09.11.2016 **Accepted:** 11.01.2017 **Available Online Date:** 05.05.2017

## Introduction

In gunshot wounds, migration or embolism of bullet retained in the body is a rare phenomenon (1, 2). In the literature, there are several studies that report regarding bullet migration as a venous, arterial, and paradoxical embolism (2-5).

This is the first study in the literature to present a case of migration of a bullet that entered from the left thigh and passed through the medial part of the right thigh and passively moved up to the common iliac vein via the external surface of the right femoral vein.

## Case Report

A 31-year-old male was referred to our department for clinical forensic medical evaluation. He was assaulted while working at his office and thus was subsequently taken to the emergency department. A bullet was found at the crime scene by the crime science investigation unit. Thus, ballistic and crime scene investigation revealed that only one bullet was shot.

The subject was injured by a firearm and was brought to the emergency department after the injury and his general condition was found to be normal with conscious mind and stable vital signs (blood pressure, 120/65 mmHg; beats per minute, 100/min).

### Address for Correspondence:

Mustafa Talip Şener, Department of Forensic Medicine, Atatürk University School of Medicine, Erzurum, Turkey  
E-mail: mustafatalipsener@gmail.com

©Copyright 2017 by Emergency Physicians Association of Turkey - Available online at [www.jemcr.org](http://www.jemcr.org)

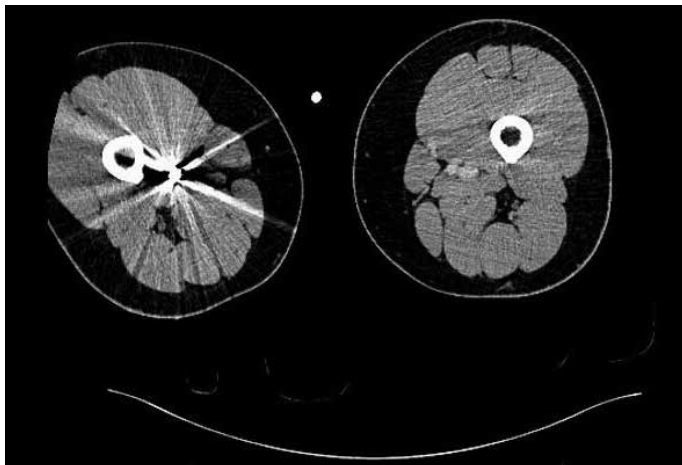


FIGURE 1. Computed tomography of the first localization of the bullet

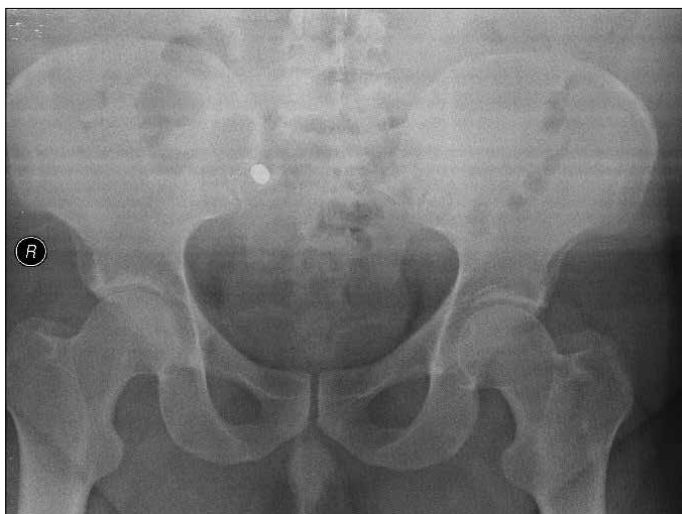

FIGURE 2. Radiographs of the localization of the bullet after 7 h

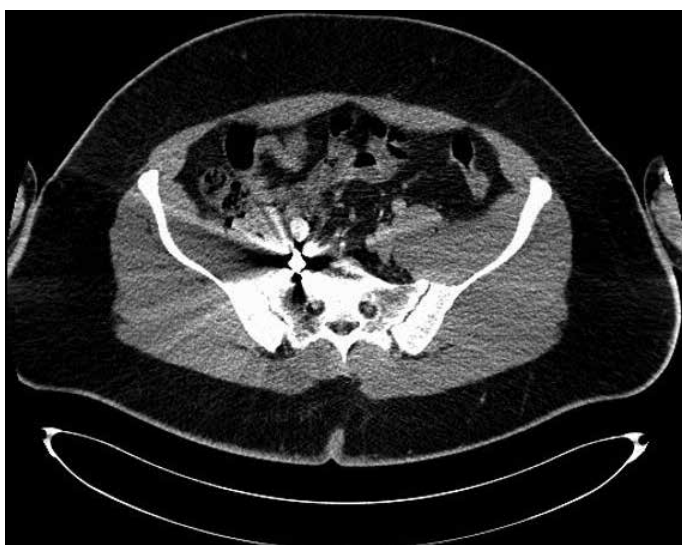

FIGURE 3. Computed tomography of the final localization of the bullet after 1 year

Non-bleeding gunshot wounds were found on the distal and medial parts of the left and right thighs, which had diameters of 1 and 2 cm, respectively. In addition, an avulsion fracture of the distal left femur was found. Radiological examinations revealed that the bullet was localized in the medial and distal parts of the right thigh (Figure 1). Right femoral venography was performed because of suspected vascular injury, and the bullet was found to be localized outside the right femoral vein. The area was washed with saline, and a broad spectrum antimicrobial solution was applied after wound debridement was completed by the orthopedist. X-ray examinations performed after 7 h revealed that the bullet in the right thigh moved to the abdomen (Figure 2). Because the localization at which the bullet was finally found was risky with respect to surgical intervention and no complication occurred during the time of observation, medical intervention was not performed to remove the bullet; periodic control was advised. The subject was discharged as no complications developed during the follow-up period and also as the bullet was observed to be localized in the same anatomical region when radiological examinations were performed after 2 and 11 months.

One year after the firearm injury, the radiology clinic was consulted to determine the exact localization of the bullet. Abdominal computed tomography revealed that the bullet, measuring 12x10 mm, was localized in the common iliac vein bifurcation at the level of the right sacroiliac articulation (Figure 3). Based on the crime scene information, we determined that the bullet first entered the left thigh and passed through the medial part of the right thigh with its own kinetic energy and then, passively moved up to the common iliac vein via the femoral space of the right femoral vein by migrating to the femoral triangle and vascular lacuna regions from the right femoral intermuscular areas. Finally, because of the spherical structure, the lead bullet was immobilized in the abdomen region. Written informed consent was obtained from the patient for publication of this case report.

### Discussion

It is known that metallic or nonmetallic objects that enter the body through various ways can migrate in the body, and this migration is caused by factors such as muscle movements from intermuscular regions, intra-abdominal pressure increase, intrathoracic negative pressure, intestinal peristalsis, blood flow in the vessel, gravity effect, and active or passive body movements (1, 6). As a result of this migration, various complications, such as pain, claudication, paresthesia, gangrene, pleural or pericardial effusion, endocarditis, thrombosis, ischemia, hemorrhage, sepsis, cardiac arrhythmias, pseudoaneurysm, toxicity, neurosis, and death, could arise in different body parts (6-8).

In the literature, there is a case report regarding the migration of a bullet, which was retained in the body, as an embolism from the periphery to the center through the venous flow (4). Considering this related study in the literature, we have not seen any bullet migration as we observed in our case. In our case, the bullet migrated from the external surface of the right femoral vein and passed through the gaps between the muscles and then, localized at the right com-

mon iliac vein bifurcation after passing through anatomical structures such as adductor canal, femoral triangle, and vascular lacuna. The path between the fascial space of the femoral vein allowed the bullet to passively migrate from the right femoral vein to the right common iliac vein bifurcation (9). The anatomical structures in the common iliac vein bifurcation and surrounding tissues may have been the main causes of ending the passive migration of the bullet. Vascular pulsation on the femoral vein surface, fascia occurring during the movement of the thigh, and pressure because of muscle contractions and negative pressure inside the thorax are the other factors with a significant effect on bullet migration in the body (10). In addition, the application of a pressure liquid solution during wound debridement may have affected the bullet migration.

### Conclusion

This case report is important as it demonstrated that a bullet retained in the body may migrate toward proximal and abdomen through the external surface of the vein between the fascia and intermuscular structures with a passive movement other than intravascular way.

**Informed Consent:** Written informed consent was obtained from patient who participated in this case.

**Peer-review:** Externally peer-reviewed.

**Author contributions:** Concept – M.T.Ş., Ç.K.; Design – M.T.Ş., Ç.K., İ.M., A.L.; Supervision – M.T.Ş., A.L., A.N.K.; Resource – M.T.Ş., Ç.K.; Materials – M.T.Ş., Ç.K., İ.M.; Data Collection and/or Processing – M.T.Ş., Ç.K., A.N.K.; Analysis and/or Interpretation – M.T.Ş., Ç.K., A.N.K.; Literature Search – M.T.Ş., Ç.K., İ.M.; Writing – M.T.Ş., Ç.K., İ.M., A.L.; Critical Reviews – M.T.Ş., İ.M., A.L., A.N.K.

**Conflict of Interest:** No conflict of interest was declared by the authors.

**Financial Disclosure:** The authors declared that this study has received no financial support.

### References

1. Meena S, Singla A, Saini P, Mittal S, Chowdhary B. Spontaneous migration of bullet from arm to forearm and its ultrasound guided removal. *J Ultrasound* 2013; 16: 223-5. [\[CrossRef\]](#)
2. Yamanari MG, Mansur MC, Kay FU, Silverio PR, Jayanthi SK, Funari MB. Bullet embolism of pulmonary artery: a case report. *Radiol Bras* 2014; 47: 128-30. [\[CrossRef\]](#)
3. Corbett H, Paulsen EK, Smith RS, Carman CG. Paradoxical bullet embolus from the vena cava: a case report. *J Trauma* 2003; 55: 979-81. [\[CrossRef\]](#)
4. Carter CO, Havens JM, Robinson WP, Menard MT, Gates JD. Venous bullet embolism and subsequent endovascular retrieval - A case report and review of the literature. *Int J Surg Case Rep* 2012; 3: 581-3. [\[CrossRef\]](#)
5. Ronsivalle J, Statler J, Venbrux AC, Arepally A. Intravascular bullet migration: a report of two cases. *Mil Med* 2005; 170: 1044-7. [\[CrossRef\]](#)
6. Biswas S, Price C, Abrol S. An elusive bullet in the gastrointestinal tract: a rare case of bullet embolism in the gastrointestinal tract and a review of relevant literature. *Case Rep Crit Care* 2014; 689539. [\[CrossRef\]](#)
7. Lu XH, Lu ZJ, Hu J, Song JX, Chen SL. Bullet migration from the knee to the heart after a gunshot injury: a case report. *Chin Med J (Engl)* 2011; 124: 1590-2.
8. Farrugia A, Raul JS, Géraut A, Ludes B. Ricochet of a bullet in the spinal canal: a case report and review of the literature on bullet migration. *J Forensic Sci* 2010; 55: 1371-4. [\[CrossRef\]](#)
9. Moore KL, Dalley AF, Agur AMR. Lower limb. In *Clinically oriented anatomy*. 7th ed. Philadelphia: Lippincott Williams & Wilkins; 2013.p.508-669.
10. Standring S, Editor. Pelvic girdle and lower limb: overview and surface anatomy. In *Gray's Anatomy. The Anatomical basis of clinical practice*. 40th Edition. Churchill Livingstone: Elsevier; 2008.p.1327-48.